

Asian Journal of Phytomedicine and Clinical Research

Journal home page: www.ajpcrjournal.com



HISTOLOGICAL EFFECTS OF *ELAEOAGNUS ANGUSTIFOLIA* AQUEOUS EXTRACT ON CARTILAGE DEGRADATION IN EXPERIMENTAL OSTEOARTHRITIS

Mahtab Maghzi^{1,2*}, Layasadat Khorsandi^{1,2}, Mahmoud Orazizadeh², Kheironesa Ahmadi³

¹Student Research committee, Ahvaz Jundishapur University of Medical Sciences, Ahvaz, Iran.

^{2*}Cell and Molecular Research Center, Faculty of Medicine, Ahvaz Jundishapur University of Medical Sciences, Ahvaz, Iran.

³Department of Anatomical Sciences, Faculty of Medicine, Ahvaz Jundishapur University of Medical Sciences, Ahvaz, Iran.

ABSTRACT

To evaluate the anti-osteoarthritis activity of *Elaeagnus angustifolia* fruit extract (EAE) in Mono-iodoacetate (MIA) induced osteoarthritis (OA). Forty Adult male Wistar rats were used in this experiment. MIA was injected in right knee joints to induce OA. Oral treatment with EAE at the doses of 250, 500 and 1000 mg/kg was started on day 14 after MIA injection and was continued until the study was terminated on day 28. Then the rats were sacrificed and the right knee joints were removed, fixed in 10% formalin and decalcified for histological studies. Very poor anti-OA property was observed in MIA+250 mg/kg EAE treated group. Histological changes, cellularity and matrix staining of articular cartilage in MIA+500 mg/kg EAE treatment were significantly changed compared to MIA treated animals. These effects were considerably more in MIA+1000 mg/kg EAE treated animals. Our results demonstrate that EAE can effectively improve OA- induced by MIA in a dose-dependent manner and might be clinically useful.

KEYWORDS

Russian olive, Osteoarthritis and Animal model.

Author for Correspondence:

Mahtab Maghzi,
Cell and Molecular Research Center, Faculty of
Medicine, Ahvaz Jundishapur University of
Medical Sciences, Ahvaz, Iran.

Email: Mahtabmaghzi@yahoo.com.

INTRODUCTION

Osteoarthritis (OA) is a typical slow and degenerative joint disease. It affects about 80% of individuals of both sexes over the age of 60 and nearly 15% of population¹. Existing treatments for OA provide pain relief and some anti-inflammatory effects, but no truly disease-modifying treatments are available for this disease. Traditionally, plants have been used for centuries as a popular method for

treating several health disorders. *Elaeagnus angustifolia* (EA) or Russian olive is one of these herbs applied most in Iran's traditional medicine. Phytochemical studies have shown that aqueous fruit extract of EA (EAE) contains flavonoids compounds, sitosterols, cardiac glycosides and terpenoids^{2, 3}. It has been reported that EAE reduces pain and inflammation^{4, 5}, and has Muscle relaxant activity⁶. In present study, the effects EAE on OA-induced by Mono-iodoacetate (MIA) in rats were investigated. Intra-articular injection of MIA induces chondrocyte death in the articular cartilage of rodent and nonrodent species. When used in rodents, the model reproduces cartilage lesions with loss of proteoglycan matrix and functional joint impairment similar to human OA⁷.

MATERIALS AND METHOD

Animals

In this experimental study, 48 healthy and adult male Wistar rats (8-10 weeks old, 300-350g) were used. The animals were obtained from Ahvaz Jundishapur University of Medical Sciences, Experimental Research Center, and this study was approved by the ethics committee of Jundishapur University and carried out in an ethically proper way by following the guidelines provided. The animals were kept under standard laboratory conditions (12 h-dark and 12 h- light cycle, relative humidity of $50 \pm 5\%$ and $22 \pm 3^\circ\text{C}$) for at least 1 week before the experiment and those conditions were preserved until the end of the experiment. Animal cages were kept clean, and commercial food (pellet) and water were provided *ad libitum*.

Experimental design

The rats were randomly divided in to 6 groups. 50 μl of saline was injected in right knee joints in control group. In order to induce OA 1mg of MIA dissolved in 50 μl saline and injected in right knee joints⁷. Oral treatment with EAE at the doses of 250, 500 and 1000 mg/kg was started on day 14 after MIA injection and was continued until the study was terminated on day 28. In the end of experiment all rats were sacrificed by cervical dislocation under ether anesthesia. The knee joints of the rats were

fixed in 10% buffered formalin, decalcified in hydrochloric acid, and embedded in paraffin. 5 μ sections were stained with hematoxylin and eosin (H and E) for routine histologic evaluation. Safranin-O and toluidine blue staining was also done to identify proteoglycans. A modified Mankin system was used to score cartilage changes. The scale evaluates the loss of safranin-O staining (scale 0-4), cellular changes (scale 0-3), invasion of the tide mark by blood vessels (scale 0-1) and structural changes (scale 0-6). Scoring was based on the most severe histologic changes within each cartilage section⁸.

Preparation of Extract

The aqueous extract was prepared by adding 2000 ml of distilled water to 100 g of fruit powder (without cores) and the resulting solution was boiled for 10 minute. Then the mixture was filtered and the solution was completely dehydrated for 8 to 10 hours in water bath to provide a crude extract⁹.

Statistical analysis

The data were analyzed using one-way ANOVA followed by post hoc LSD test and were presented as the mean \pm SD. $p < 0.05$ was considered significant.

RESULTS AND DISCUSSION

The joints of MIA-induced OA showed severe discontinuity, degeneration of the articular cartilage and disappearance of chondrocytes in the tangential, transitional and radial zones of the cartilage. The cellularity of articular cartilage was significantly decreased ($p < 0.001$). Sections stained with safranin-O and Toluidine blue revealed severe reduction in their staining indicating proteoglycans loss (Figure No.1). Treatment with 250 mg/kg of EAE had little effect on the structural changes in the joints induced by MIA. Mankin grading showed no significant change ($p > 0.05$) compared to the MIA treated joints. In 500 mg/kg of EAE group, histological changes were considerably reversed. Cellularity and matrix staining of articular cartilage were significantly changed ($p < 0.01$) compared to MIA treatment. Mankin grading was also significantly decreased. Treatment with 1000 mg/kg of EAE effectively improved the structural changes

in the joints induced by MIA. Cellularity and matrix staining of articular cartilage in this group were significantly increased compared to MIA treated joints. These findings are shown in Table No.1. In MIA group vascularization in articular joints was observed. The vascularization of articular joints in MIA+250 mg/kg of EAE group were slightly less than MIA treatment. There were not any signs of vascularization in other groups. This study demonstrated that EAE at the doses of 500 and 1000 mg/kg could effectively improve OA induced by MIA. MIA induced a significant decrease in chondrocyte population in articular cartilage. The cellularity of articular cartilages was considerably reversed in 1000 mg/kg of EAE treated animals. Actually, saving plausible number of cartilage cells in the joint articular structure is important in OA pathology and progression, because chondrocytes are the only component capable of controlling vital activities of the articular cartilage. In addition to changes in the cellularity, the matrix staining was reduced in MIA treated joints. Proteoglycan depletion could be secondary to cell loss due to the osteoarthritic process. EAE at the doses of 500 and 1000 mg/kg was able to increase the cellularity and matrix staining. These findings indicate that EAE at this dosage can effectively suppress OA. Vascularization in damaged cartilages was observed in MIA and MIA+ 250 mg/kg EAE treated animals.

It is well known that vascularization of the damaged articular cartilage is accompanied by innervations, which contributes to pain¹⁰. Although pain was not measure in this study, it is possible that EAE relieves pain by inhibiting vascularization after MIA treatment. Clinical and animal studies showed that using EAE inhibits pain and inflammation in animal models^{4, 10}. Alishiri *et al.* has reported that the fruit's tea of EA can reduce rheumatoid arthritis pain¹¹. The exact mechanism of therapeutic effects of EAE on MIA-induced OA is not obtained from this study. EAE can slow down the production of free radicals that may be found in the articular tissue of joints suffering OA, because EAE has antioxidant activity¹². Flavonoids have been considered one of the most important constituents in EAE^{5, 13}.

Previous studies have demonstrated that flavonoids and sitosterols are responsible for anti-inflammatory and analgesic effects of this plant¹⁴. Flavonoids and dietary antioxidants have been shown to slow the progression of OA¹⁵. In this way, EAE may exert its therapeutic effects on the MIA rat model of OA not only through its antioxidant activity, but also through its anti-inflammatory activity. Another mechanism is that EAE may suppress the apoptosis in the joint. Flavonoids have been found to have a potent anti-apoptotic activity^{16, 17}. Therefore, EAE may restore chondrocytes, which are capable of preventing the matrix degradation.

Table No.1: Mankin grading of knee joints in control and experimental groups (mean ± SD)

Groups	Structure	Cellularity	Matrix Staining	Tidermark integrity	Total mankin
Control	0.04±0.009	0.29±0.07	0.16±0.08	0	0.49±0.7
MIA	4.1±0.4**	2.9±0.2**	3.85±0.06**	0.43±0.07**	11.28±0.08**
MIA+250mg/kg EAE	3.9±0.6**	2.8±0.2**	3.3±0.1**	0.27±0.07**†	9.67±0.9**
MIA+500mg/kg EAE	1.8±0.3**†	1.7±0.08**†	1.8±0.02**††	0.08±0.004**††	5.69±0.8***†
MIA+1000mg/kg EAE	0.84±0.07*†	0.6±0.06*†	0.9±0.02**††	0††	2.34±0.4***††

Note: Compared with control group, * $p < 0.01$, ** $p < 0.001$; Compared with MIA group, † $p < 0.01$, †† $p < 0.001$.

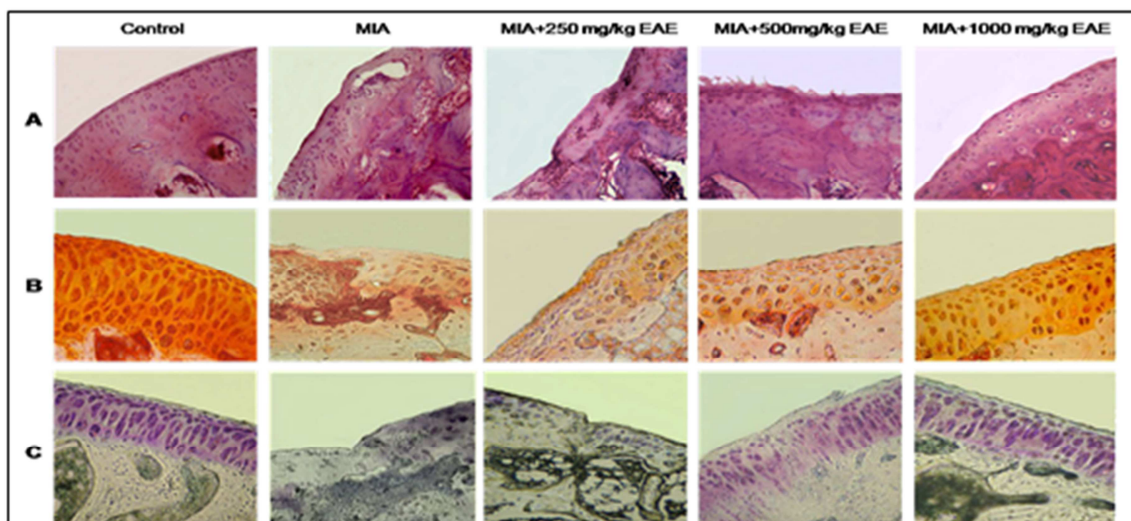


Figure No.1: Light microscopy of knee joints

A: H and E staining, B: Safranin O staining, C: Toluidine blue staining, 250×.

CONCLUSION

At this stage, it is difficult to say which component(s) of fruit extracts are responsible for this chondro-protective activity. Further phytochemical investigation is required to isolate the active compound(s) responsible for these pharmacological properties and to understand the complete mechanism of chondro-protective activity of EAE. Extrapolation of the sedata to the human situation is not appropriate. However, this information does provide a stimulus for true clinical investigation.

ACKNOWLEDGMENT

This study was supported by a Grant (92s42) from Student Research committee of the Ahvaz Jundishapur University of Medical Sciences in 2013.

CONFLICT OF INTEREST

We declare that we have no conflict of interest.

BIBLIOGRAPHY

1. Goldring M B, Goldring S R. Osteoarthritis, *Cell Physiol*, 213(3), 2000, 626-34.
2. Farahbakhsh S, Arabian S, Emami F, Rastegar Moghadam B, Ghoshooni H, Noroozadeh A, *et al.* Inhibition of cyclooxygenase type 1 and 2 enzyme by aqueous extract of *Elaeagnus angustifolia* in mice, *Basic Clin Neuroscience*, 2(2), 2011, 31-7.
3. Debinska Migas W, Gill S. Flavonoids in leaves of *Elaeagnus angustifolia* L. *Pol J Pharmacol Pharm*, 25(6), 1973, 599-606.
4. Ramezani M, Hosseinzadeh H, Daneshmand N. Antinociceptive effect of *Elaeagnus angustifolia* fruit seeds in mice, *Fitoterapia*, 72(3), 2001, 255-62.
5. Ahmadiani A, Hosseini J, Semnani S, Javan M, Saeedi F, Kamalinejad M *et al.* Antinociceptive and antiinflammatory effects of *Elaeagnus angustifolia* fruit extract, *J Ethnopharmacol*, 72(1-2), 2000, 287-92.
6. Hosseinzadeh H, Ramezani M, Namjo N. Muscle relaxant activity of *Elaeagnus angustifolia* L. fruit seeds in mice, *J Ethnopharmacol*, 84(2-3), 2003, 275-8.
7. Bar-Yehuda S, Rath-Wolfson L, Del Valle L. Induction of an anti-inflammatory effect and prevention of cartilage damage in rat knee osteoarthritis by CF101 treatment, *Arthritis Rheum*, 60(10), 2009, 3061-71.
8. Mankin H J, Dorfman H, Lippiello L, Zarins A. Biochemical and metabolic abnormalities in articular cartilage from osteo-arthritic human hips, II. Correlation of morphology with biochemical and metabolic data, *J Bone Joint Surg Am*, 53(3), 1971, 523-7.

9. Mehrabani Natanzi M, Pasalar P, Kamalinejad M, Dehpour A R, Tavangar S M, Sharifi R et al. Effect of aqueous extract of *Elaeagnus angustifolia* fruit on experimental cutaneous wound healing in rats, *Acta Med Iran*, 50(9), 2012, 589-96.
10. Suru S, Gill S E, Massena De Camin S, Wilson D, McWilliams D F, Walsh D A. Neurovascular invasion at the osteochondral junction and in osteophytes in osteoarthritis, *Ann Rheum Dis*, 66(11), 2008, 1423-8.
11. Alishiri G H, Ahmadiani A, Bayat N, et al. Evaluation of the effects *Elaeagnus angustifolia* fruit extract in patients with knee osteoarthritis a double-blind completely randomized placebo clinical trial, *Kowsar Medical J*, 12(2), 2007, 39-57.
12. Cansev A, Sahan Y, Celik G, Taskesen S, Ozbey H. Chemical Properties and Antioxidant Capacity of *Elaeagnus angustifolia* L Fruits, *Asian J Chem*, 23(6), 2011, 2661-5.
13. Erdemoglu N, Akkol E K, Yesilada E, Calis I. Bioassay-guided isolation of anti-inflammatory and antinociceptive principles from a folk remedy, *Rhododendron ponticum* L leaves, *J Ethnopharmacol*, 119(1), 2008, 172-8.
14. Kupeli E, Yesilada E. Flavonoids with anti-inflammatory and antinociceptive activity from *Cistus laurifolius* L leaves through bioassay-guided procedures, *J Ethnopharmacol*, 112(3), 2007, 524-30.
15. Mc Alindon T, Zhang Y, Hannan M, Naimark A, Weissman B, Castelli W, et al. Are risk factors for patellofemoral and tibiofemoral knee osteoarthritis different, *J Rheumatol*, 23(2), 1996, 332-7.
16. Schroeter H, Spencer J P, Rice-Evans C Williams R J. Flavonoids protect neurons from oxidized low-density-lipoprotein-induced apoptosis involving c-Jun N-terminal kinase (JNK), c-Jun and caspase-3, *Biochem J*, 358(3), 2001, 547-57.
17. Zou YP, Lu Y H, Wei D Z. Protective effects of a flavonoid-rich extract of *Hypericum perforatum* L. against hydrogen peroxide-induced apoptosis in PC12 cells, *Phytother Res*, 24(4), 2010, 632.

Please cite this article in press as: Mahtab Maghzi et al. Histological Effects of *Elaeagnus Angustifolia* Aqueous Extract on Cartilage Degradation in Experimental Osteoarthritis, *Asian Journal of Phytomedicine and Clinical Research*, 3(2), 2015, 50 - 54.